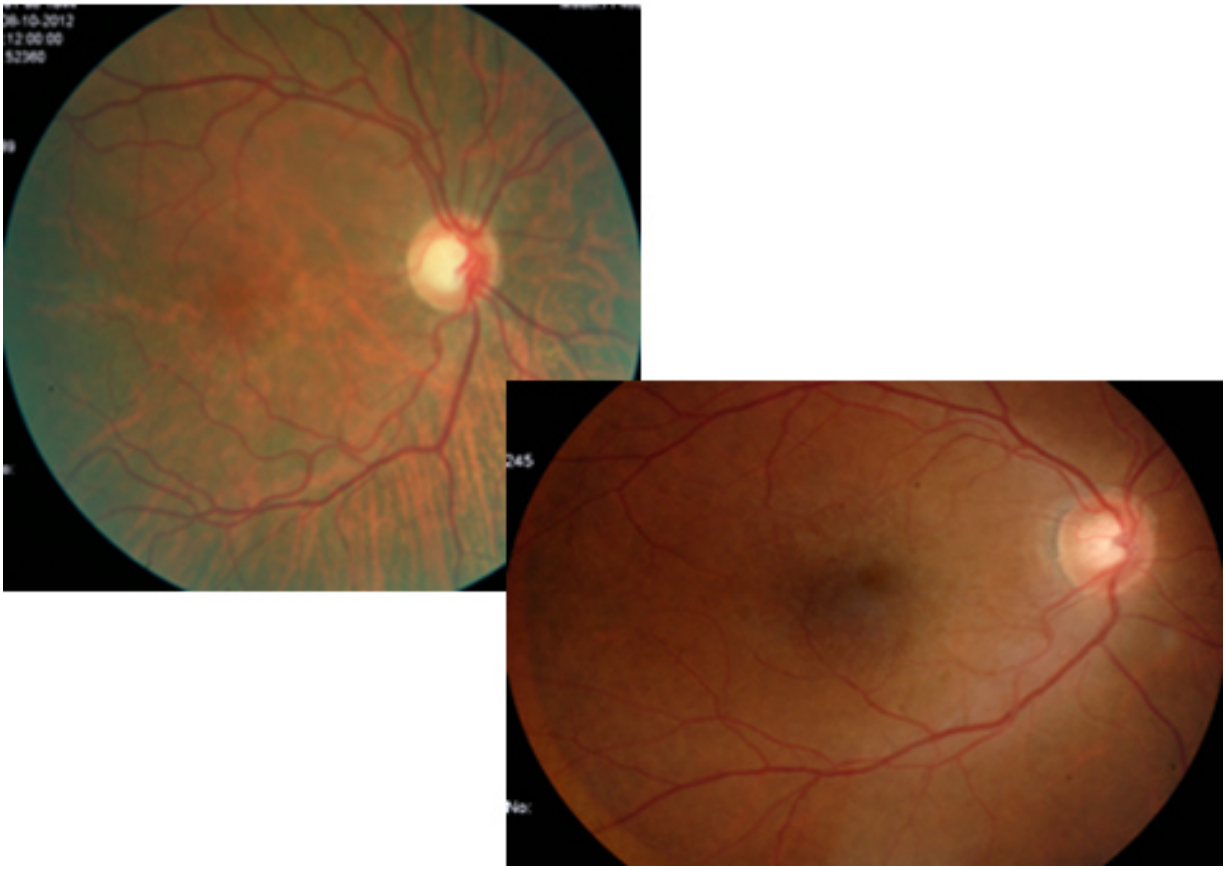

15. PATOLOGIAS DIVERSAS

15 – PATOLOGIAS DIVERSAS

- **Fundus negróide**

Fig. 15.1 Fundus negróide (Retinografia)

Fig. 15.2 Fundus negróide (Retinografia)

Fig. 15.3Fundus negróide (Anerítica)

Fig. 15.4 Fundus negróide (Anerítica)

- **Nevo OTA**

SINAIS: Aumento de pigmentação no olho ipsilateral ao nevo Ota.

Fig. 15.5 Fundo hiperpigmentado. Nevo Ota (Retinografia)

Fig. 15.6 Nevo Ota. Olho adelfo. (Retinografia)

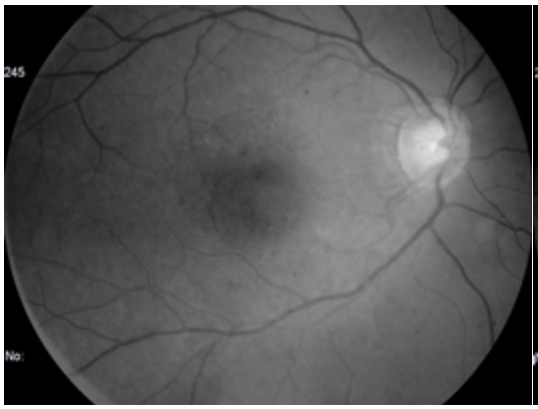

Fig. 15.7 Fundo hiperpigmentado. Nevo Ota (Anerítica)

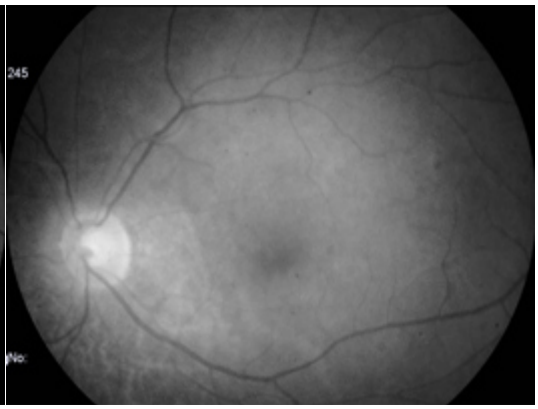

Fig. 15.8 Nevo Ota. Olho adelfo. (Anerítica)

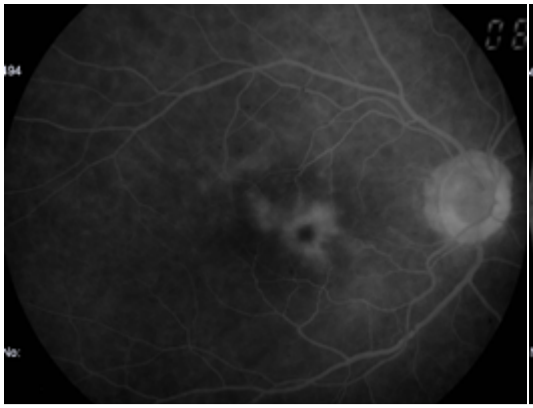

Fig. 15.9 Fundo hiperpigmentado. Nevo Ota (AF)

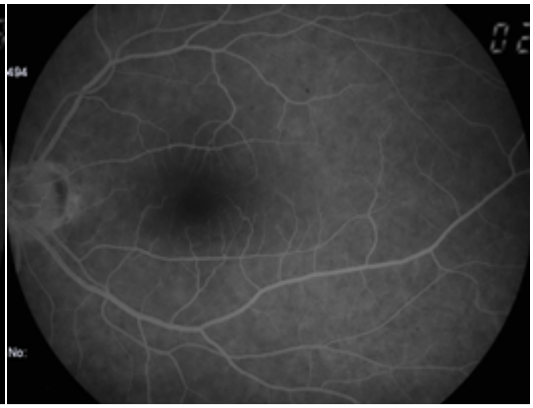

Fig. 15.10 Nevo Ota. Olho adelfo. (AF)

- **Sindrome avulsão vasos sanguíneos**

Fig 15.11 Síndrome avulsão vasos sanguíneos (Retinografia)

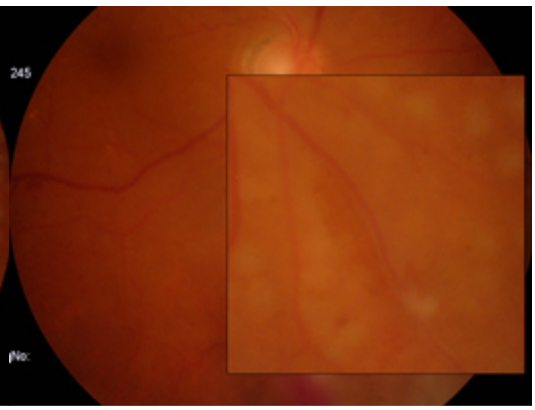

Fig 15.12 Síndrome avulsão vasos sanguíneos (Retinografia)

- **Retemirabile -like**

Fig. 15.13 Retemirabilelike (Retinografia)

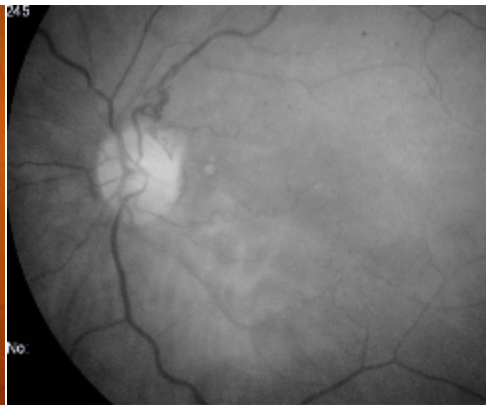

Fig. 15.14 Retemirabilelike (Anerítica)

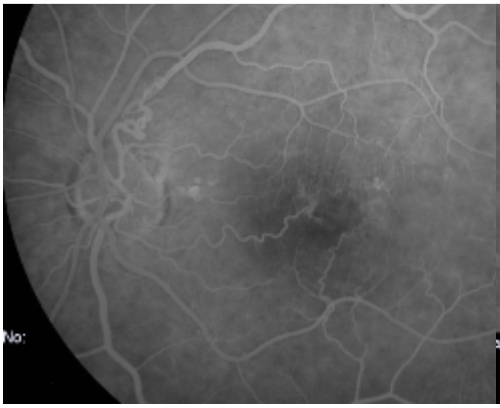

Fig. 15.15 Rete mirabile like (AF)

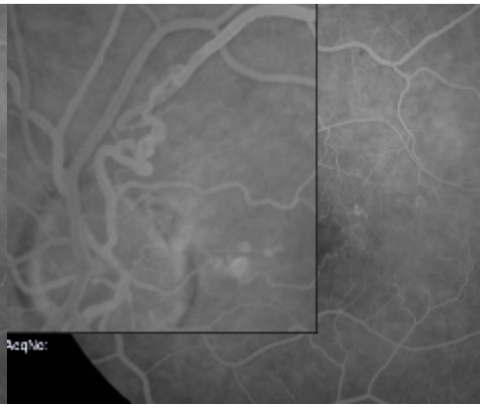

Fig. 15.16 Rete mirabile like (AF)

- **Pigmentação atípica sobre um vaso sanguíneo**

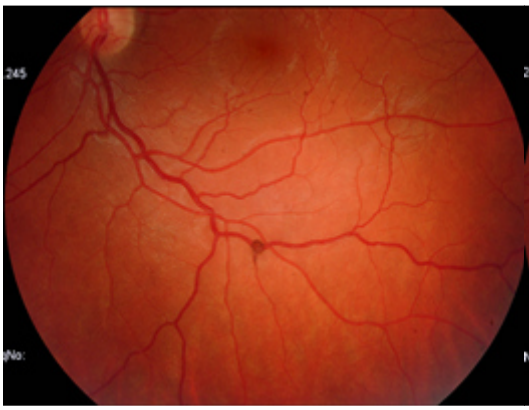

Fig. 15.17 Pigmentação atípica (Retinografia)

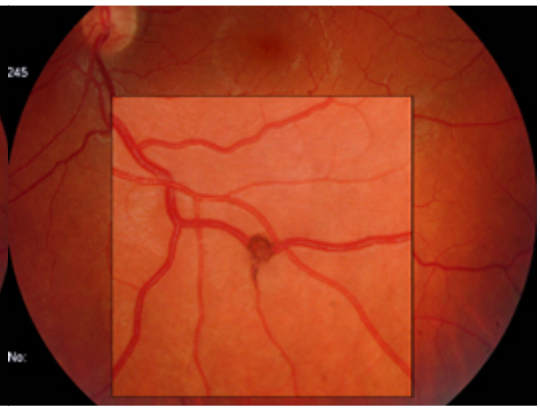

Fig. 15.18 Pigmentação atípica (Retinografia)

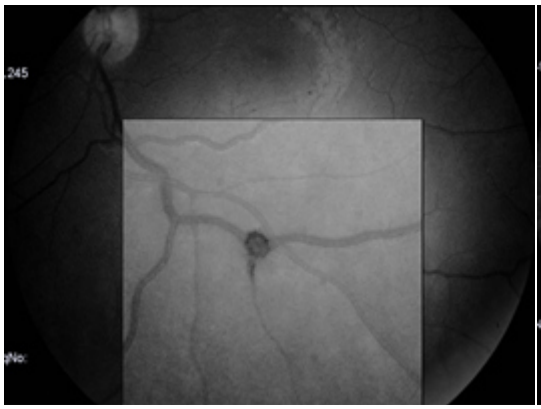

Fig. 15.19 Pigmentação atípica (Anerítica)

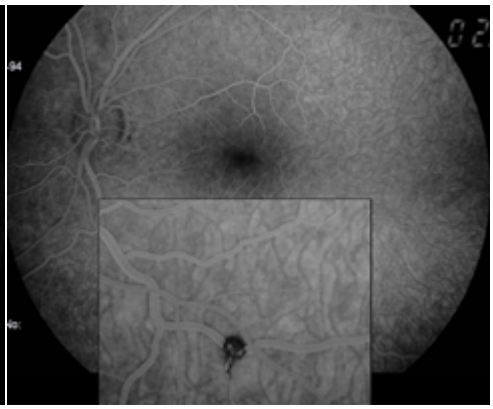

Fig. 15.20 Pigmentação atípica (AF)

- **Artefacto**

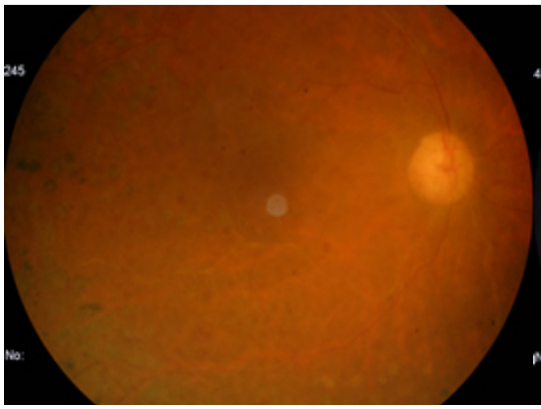

Fig. 15.21 Artefacto que simula uma maculopatia



Fig. 15.22 Artefacto que simula uma maculopatia